

# Vancomycin toxicity: An uncommon mimic of bacterial meningitis

Saumya H Mittal\*

Email: saumyamittal1@gmail.com

## Abstract

A 24-year-old woman was admitted with emesis, headache, and fever followed by seizure for seven days at the onset. The woman was initiated on treatment for bacterial meningitis. She improved on the treatment. However, over some time, she deteriorated again, and mimics of meningitis were considered. The patient was on vancomycin and on withdrawal of vancomycin, she improved. We report this case because of an uncommon cause of mimic of meningitis.

**Key words:** Bacterial meningitis, mimics of meningitis, vancomycin, ventriculitis

## Introduction

Bacterial meningitis commonly presents with the triad of fever, altered sensorium, and neck stiffness. However, all three symptoms simultaneously are present in 50% of patients or less. Almost 90–95% of patients present with just two of the symptoms of the triad. Neck stiffness, Kernig's sign, and Brudzinski's sign are the three signs of meningitis.<sup>1</sup>

Antibiotics should be initiated as soon as possible, preferably after sending a sample of blood and cerebrospinal fluid (CSF) for the culture. This helps in lower mortality. The choice of antibiotic depends on the possible pathogen and the local sensitivity. Vancomycin with a cephalosporin is the common recommendation especially after the emergence of penicillin-resistant pneumococci.<sup>1</sup>

## Case report

This 24-year-old woman presented to the hospital with a history of recurrent episodes of emesis for seven–ten days at the time of admission. On

recovery, she gave a history of mild fever and headache for seven days as well. She was received in altered sensorium after having sustained an episode of seizure suggesting a postictal state. The woman had delayed menses and she thought she was pregnant (as informed by her after improvement). She, therefore, did not inform her family about her symptoms, assuming them episodes of morning sickness associated with pregnancy. She was found to have neck stiffness. A possibility of enteric fever had been considered at another hospital and she was presented to the hospital after two days of ceftriaxone.

Since, she had seizures and was in altered sensorium a possibility of venous thrombosis was considered. Since she was pregnant, MR Venography was preferred. This was normal. EEG showed generalized slowing of waves. She was taken up for lumbar puncture and CSF analysis (report in Table 1). She was reinitiated on ceftriaxone. She was found to be pregnant, a G2P1L1 pregnancy. Therefore, vancomycin was not started initially. She improved gradually in treatment. She was taken up for medical abortion because of her choice and given any possible fetal risk. Because of meningitis and to cover the post-operative infective risk, vancomycin was then added.

**Dr Saumya H Mittal**

<sup>1</sup> MBBS, MD (Medicine), DNB (Neurology), Consultant Neurologist, Felix Hospital, Noida

\*Corresponding Author

Manuscript received : 29/11/2019

Revision accepted : 4/4/20

**How to cite this article:** Mittal SH. Vancomycin toxicity: An uncommon mimic of bacterial meningitis. *MJMS*. 2020; 5(1): 39–41.

**Table 1: Initial investigations of the patient**

CSF	TLC	50 (100% lymphocytes)
	Protein	256
	Glucose	83
	ADA	1.5
	Indian ink	Negative
	Cryptococcus	Negative
	AFB stain	Negative
	MTB gene expert	Negative
	Gram stain	Negative
	Culture	No growth
	Cytology	No malignant cells
Serum	Beta HCG	37035
	TSH	0.77
	T3	3.41
	T4	1.09
	CPK	592
	HbA1C	4.4
Urine	HCG	Positive
	Ketones	+++

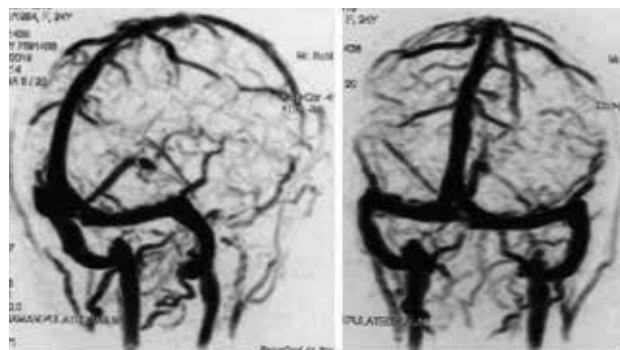
She deteriorated after two days post-operatively became more drowsy and febrile. She had severe neck rigidity now and lost consciousness on day three. Her kidney functions deteriorated and a possible septic shock was being concerned. Blood cultures, urine cultures, and CSF analysis were done (Table 2).

**Table 2: Repeated investigations after deterioration**

CSF	TLC	3 (100% lymphocytes)
	Protein	53
	Glucose	58
	ADA	1.1
	Indian ink	Negative
	Cryptococcus	Negative
	AFB stain	Negative
	MTB gene expert	Negative
	Gram stain	Negative
	Culture	No growth
	Cytology	No malignant cells
Urine	Culture	No growth
	Ketones	-
Blood	Culture	No growth
	TLC	5000

None of these was found to be significant. Ultrasound showed no retained products of conception. Also,

her total leucocyte count (TLC) remained normal. She however developed azotaemia. Because of azotaemia developing after initiation of vancomycin, a possibility of drug reaction was considered and the medicine was withdrawn. No other treatment changes were made. The patient's kidney function test (KFT) improved over the next two days and she improved completely and was discharged four days thereafter with no deficits.

**Fig 1: No evidence of CVT on MR Venogram**

## Discussion

Diagnosing meningitis can often be difficult since many other illnesses present with similar presentations. Differential diagnosis includes viral meningitis, other infective meningitis, autoimmune conditions like rheumatoid arthritis and lupus. Malignancy, subarachnoid haemorrhage, and migraine are some other mimics. Medication reactions such as those to non-steroidal anti-inflammatory medications can sometimes mimic the syndrome. Pneumonia, otitis, pharyngitis, gastroenteritis, enteric fever, febrile convulsions, cyanotic spells, milk allergy, and even vitamin A toxicity are other mimics reported by authors previously.<sup>1,2</sup>

Antibiotics should be initiated as soon as possible, preferably after sending a sample of blood and CSF for the culture. This helps in lower mortality. The choice of antibiotic depends on the possible pathogen and the local sensitivity. Vancomycin with a cephalosporin is the common recommendation for bacterial meningitis especially after the emergence of penicillin-resistant pneumococci.<sup>1</sup>

Vancomycin molecules are large glycopeptides that bind irreversibly to the cell wall. It is used to treat gram-positive organisms. The drug toxicity of vancomycin is known commonly due to the dose and frequency of the medicine, comorbidities such as obesity and renal dysfunction and other medications being administered.<sup>3</sup> Vancomycin causes ventriculitis secondary to axonal injury. Ventriculitis is characterized by choroid plexitis. Ventriculitis in the setting of meningitis, however, has no additional significance.<sup>4, 5, 6</sup>

Prognosis is said to be poor if there is associated thrombocytopenia. Hearing loss, limb loss, meningococcal sepsis, subdural empyema, hydrocephalus, and seizures are known sequelae. Neurocognitive dysfunction and sleep disorders are other known sequelae.<sup>1</sup>

### Conclusion

Vancomycin is one of the antibiotics that is empirically initiated in patients suspected of bacterial meningitis. Here we present a case where the antibiotic itself led to the deterioration of the sensorium and meningismus. Hence, in any patient of bacterial meningitis, who is not improving and septicaemia is being considered, vancomycin toxicity

should be considered and a withdrawal of the medication should be considered before moving to higher antibiotics in this era of antibiotic resistance.

### References

1. McGill F, Heyderman RS, Panagiotou S, Tunkel AR, Solomon T. Acute Bacterial Meningitis in Adults. *The Lancet*. 2016; 388(10063):3036-47.
2. Levy M, Wong E, Fried D. Diseases That Mimic Meningitis-Analysis of 650 Lumbar Punctures. *Clinical Pediatrics*. 1990;29(5):254-61.
3. Lee P, DrPersio D, Jerome RN, Wheeler AP. Approaching and Analyzing a Large Literature on Vancomycin Monitoring and Pharmacokinetics. *J Med Libr Assoc*. 2007;95(4):374-80.
4. Grill MF, Maganti RK. Neurotoxic Effects Associated with Antibiotic Use: Management Considerations. *British Journal of Clinical Pharmacology*. 2011;72(3):381-93.
5. Rezaei NJ, Bazzazi AM, Naseri Alavi SA. Neurotoxicity of the antibiotics: A comprehensive study. *Neurol India* 2018;66:1732-40.
6. Bruniera FR, Ferreira FM, Saviolli LRM, et al. The use of vancomycin with its therapeutic and adverse effects: a review. *European Review for Medical and Pharmacological Sciences*. 2015;19: 694-700.